

Angioleiomyoma of Uterus - Case Report of a Rare Variant

Akanksha Sharma¹, Deepti Goswami², Gauri Gandhi³

¹Scientist-C, Indian Council of Medical Research, New Delhi

^{2,3}Professor, Department of Obstetrics and Gynecology,
Maulana Azad Medical College and Lok Nayak Hospital, New Delhi

Corresponding Author: Akanksha Sharma

ABSTRACT

Angioleiomyoma is a rare variant of leiomyoma originating from smooth muscle cells and characterised by thick walled blood vessels. It usually occurs in the subcutaneous tissue of the lower extremities. Only a limited number of cases have been reported to involve uterus. It causes heavy menstrual bleeding and dysmenorrhea due to dysregulation of growth factors like basic fibroblast growth factor affecting angiogenesis. There are no specific clinical and radiological features which can differentiate it from leiomyoma; hence the diagnosis is usually possible only after histopathological examination. Here, we are presenting a case report of 35 year old woman who came to us with complaints of menorrhagia and pain abdomen. She was diagnosed to have leiomyoma uterus for which myomectomy was done and the final histopathological report came out to be angioleiomyoma of uterus.

Keywords: Angioleiomyoma, Leiomyoma variant, Vascular leiomyoma.

INTRODUCTION

Angioleiomyoma is a unique benign variant of leiomyoma composed of smooth muscle cell swirling around thick walled hyalinised blood vessels. It is found commonly in the subcutaneous tissues especially of lower extremities and rarely involves uterus. Only a limited number of cases of uterine angioleiomyomas have been reported in literature. It generally manifests in the fourth to sixth decades with heavy menstrual bleeding, pain or mass in abdomen. It alters angiogenesis by

dysregulation of basic fibroblast growth factor which accounts for menorrhagia and dysmenorrhea in these patients. The final diagnosis of angioleiomyoma is possible only after histopathological examination as there are no definitive clinical and imaging studies which can separate it from leiomyoma.

CASE HISTORY

A woman aged 35 years para 1 live 1 came to our Gynaecology outpatient department with complaints of heavy menstrual bleeding and pain abdomen for 6 months. At the time of presentation, she reported continuous bleeding for one month with passage of clots and severe dysmenorrhoea for 6 months. There was no past history of any medical or surgical disorder. On examination 16 weeks mass was palpable per abdomen arising out of the pelvis. On per vaginum examination uterus was uniformly enlarged to 16 weeks, mobile, non-tender and bilateral adnexa were normal. Her hemoglobin on admission was 8.6 gm %, for which she was given therapeutic iron supplementation in combination with tranexamic acid to build up her haemoglobin levels. Her CA-125 levels were normal. TVS showed a bulky uterus with echogenic polypoidal mass in endometrial cavity measuring 8 X 7.5 cm with evidence of internal vascularity ([Figure 1](#)). Overlying myometrium was thinned out and bilateral adnexa were normal. MRI pelvis showed enlarged uterus (11.5 x 8.8 x

14.5 cm) with a large heterogeneously enhancing polypoidal lesion measuring 10.7 x 9 x 7.4 cm in the anterior myometrium

displacing endometrial cavity posteriorly likely intramural fibroid with cystic degeneration (Figure 2).

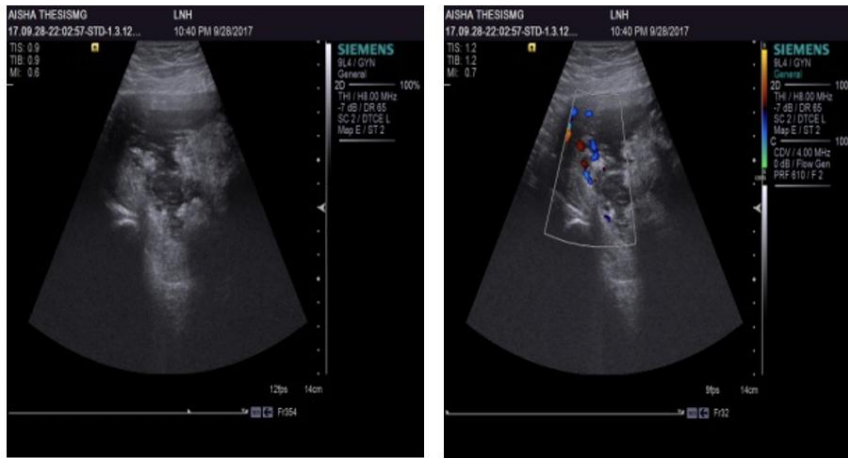


Figure 1: Trans vaginal ultrasound showing – bulky uterus with echogenic polypoidal mass in endometrial cavity measuring 8 X 7.5 cm with evidence of internal vascularity. Myometrium thinned out, likely neoplastic mass. Right ovary normal, and left adnexa clear.

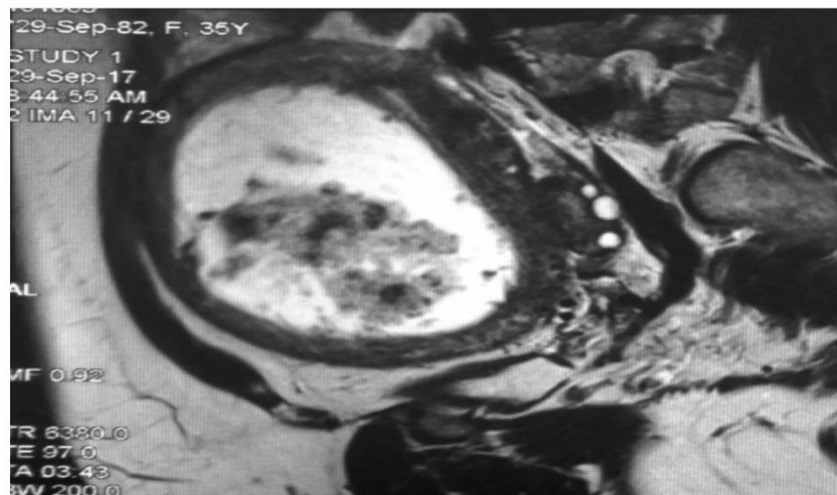


Figure 2: MRI pelvis showing enlarged uterus with a large heterogeneously enhancing lesion in anterior myometrium displacing endometrial cavity posteriorly; likely intramural fibroid showing cystic degeneration.

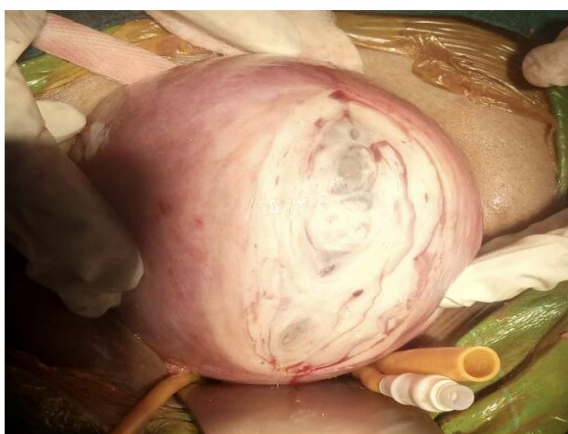

Figure 3: On gross examination uterus is enlarged to 14 weeks size and a fibroid measuring 12 x 10 x 10 cm is seen anteriorly.

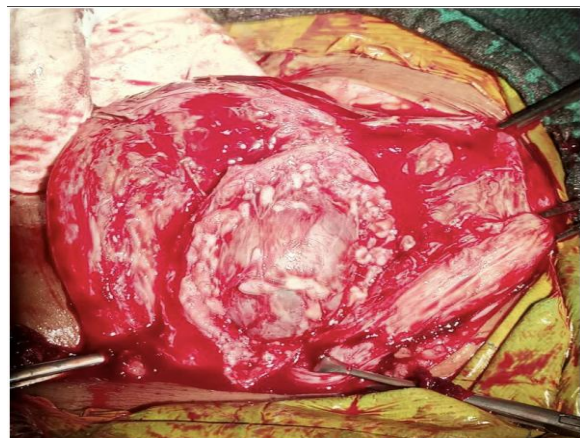


Figure 4: Cut section shows whorled appearance and areas of cystic degeneration.

She underwent an abdominal myomectomy considering a diagnosis of uterine leiomyoma. Per-operatively uterus was enlarged to 14 weeks size and a fibroid measuring 12 x 10 x 10 cm was seen anteriorly (Figure 3). On cut section, the specimen was tan-white in colour with distinctive whorled appearance and presence of haemorrhagic areas with cystic degeneration (Figure 4). The enucleation of myoma was performed following which it was sent for frozen section which was reported to be leiomyoma without any evidence of malignancy. The histopathological examination showed fascicles of smooth muscle cells interlacing with thick walled blood vessels. Hyaline degeneration was prominent in the lesion with no areas of cytological atypia, mitosis or necrosis; these features were consistent with angioleiomyoma. The patient had an uneventful course in post-operative period. However, she did not follow up with us after surgery.

DISCUSSION

Angioleiomyoma is a benign mesenchymal tumor which occurs commonly in the subcutaneous tissues of the lower extremities [1] but can also be seen in the retroperitoneum and head and neck region. Only a very few cases of uterine angioleiomyomas have been reported till date. Handler et al. quoted 11 cases of uterine ALs, Diwaker et al. found 15 cases and Sharma et al. reported 16 cases in English literature [2]. They develop during angiogenesis due to smooth muscle cells proliferation leading to vascular wall thickening [3,4]. Basic fibroblast growth factor has a unique role in this pathology. Although the genetic basis of this monoclonal tumor is not well known, karyotypic abnormalities are present in 40% of these tumors [5].

It usually occurs in middle aged females (30 to 69 years). Most commonly, patients present with heavy menstrual bleeding, pain abdomen or abdominal mass. The dysregulation of basic fibroblast growth

factors and their receptors results in abnormal uterine bleeding and local ischemia from vessel contraction causes pain [6,7]. Anemia is often encountered in these women as a result of heavy menstrual bleeding. Our patient presented at the age of 35 years with similar clinical features.

Angioleiomyoma arising in uterus exhibits as a well circumscribed mass which can present in submucosal, intramural or sub serosal location [8-10]. On cut section, surface is tan-white with whorled appearance and hemorrhagic areas like in our case.

Uterine angioleiomyoma is histologically comprised of fascicular muscle cells arranged in bundles intermingled with prominent thick walled hyalinized vessels. This histological architecture differentiates it from leiomyoma counterpart in which density of blood vessel network is analogous to normal myometrium. Angioleiomyoma consists of thick-walled muscular vessels whereas in usual leiomyomas the blood vessels are predominantly capillaries with few arteries and arterioles. Angioleiomyoma consists of 3 histologic sub-divisions on the basis of relationship between spindle muscle cell bundles and blood vessels. The most common is capillary and solid type (67%) like in our case followed by venous (23%) and cavernous type [10]. Most of these tumors lack mitotic figures, pleomorphism and necrosis [6,7]. However, a few cases with cytological atypia have been described, hence, comprehensive sampling must be done in all these cases to exclude leiomyosarcoma. Other changes occurring in angioleiomyoma are hyalinization of stroma, fibrin deposition, myxoid changes and degenerative changes with cavernous deformation of the vessels [6-10]. The microscopic diagnosis of angioleiomyoma uterus comprises of angiomyofibroblastoma, perivascular epithelioid tumor and endometrial stromal nodule. The overlapping histological findings of microscopic variants necessitate the use of immunohistochemical staining to reach a

correct diagnosis. The mainstay of treatment of angioleiomyoma is complete excision by means of hysterectomy or myomectomy with margins free of the tumour. Most cases have an uneventful post-operative course like in our case with very low risk of recurrence and excellent prognosis.

CONCLUSION

AL is a unique variant of uterine smooth muscle neoplasm that exhibit characteristic morphology and immunophenotypic features. AL has no specific imaging findings to differentiate it from other smooth muscle neoplasm and hence pre-operative differential diagnosis from other tumours is extremely difficult. Therefore, it is important for the clinician and surgical pathologist to recognize this rare benign entity and differentiate it from its mimickers including endometrial stromal tumour and leiomyosarcoma by thorough sampling and when required utilizing a proper immunohistochemistry panel.

ACKNOWLEDGMENT

We thank the patient for providing permission to publish this report.

REFERENCES

1. Weiss SW, Goldblum JR. Benign tumors of smooth muscle. In: Weiss SW, Goldblum JR, editors. *Enzinger and Weiss's Soft Tissue Tumors*. 4th ed. St. Louis: Mosby; 2001. p. 699-700.
2. Hale Demir, Kemal Gungorduk, Övgü Aydın, Şennur İlvan, Sergülen Dervisoglu. Uterine Angioleiomyoma: Case Report.

- Turkiye Klinikleri J Case Rep 2014; 22(2): 69-73.
3. Koerselman J, van der Graaf Y, de Jaegere PP, Grobbee DE. Coronary collaterals: an important and underexposed aspect of coronary artery disease. *Circulation* 2003; 107: 2507-2511.
4. Van Royen N, Piek JJ, Schaper W, et al. Arteriogenesis mechanisms of collateral artery development. *J Nucl Cardiol* 2001; 8: 687-693.
5. Hennig Y, Caselitz J, Stern C, et al. Karyotype evolution in a case of uterine angioleiomyoma. *Cancer Genet Cytogenet* 1999; 108: 79-80.
6. Hsieh CH, Lui CC, Huang SC, Ou YC, ChangChien CC, Lan KC, et al. Multiple uterine angioleiomyomas in a woman presenting with severe menorrhagia. *Gynecol Oncol*. 2003; 90:348-52.
7. Culhaci N, Ozkara E, Yüksel H, Ozsunar Y, Unal E. Spontaneously ruptured uterine angioleiomyoma. *Pathol Oncol Res*. 2006; 12:50-1.
8. Koshy A., Chaturvedula L., Habeebullah S., Basu D.: "Angiomyoma of the uterus: case report and review of literature". *Gynecol. Surg.*, 2008, 5, 169.
9. Handler M, Rezai F, Fless KG, et al. Uterine angioleiomyoma complicated by consumptive coagulopathy. *Gynecol Onkol Case Rep* 2012; 2: 89-91.
10. Hachisuga T, Hashimoto H, Enjoji M. Angioleiomyoma. A clinicopathological reappraisal of 562 cases. *Cancer*. 1984; 54: 126-30.

How to cite this article: Sharma A, Goswami D, Gandhi G. Angioleiomyoma of uterus - case report of a rare variant. *International Journal of Science & Healthcare Research*. 2021; 6(1): 140-143.
