

## Suppurative Bacille Calmette-Guerin (BCG) Lymphadenitis in an Infant- An Unexplored Entity

Dr. Manju Kumari<sup>1</sup>, Dr. Mukul Singh<sup>2</sup>, Dr. Pallavi Punhani<sup>3</sup>

<sup>1</sup>Senior Resident, <sup>2</sup>Professor, <sup>3</sup>Post graduate

Department of Pathology, Vardhman Mahavir Medical College and Safdarjung Hospital, New Delhi

Corresponding Author: Dr. Mukul Singh

### ABSTRACT

Bacilli Calmette-Guerin (BCG) is a live attenuated vaccine first used in 1921 for prevention of tuberculosis. It is administered intradermally at the time of birth. Ipsilateral axillary lymphadenopathy is a complication of this vaccine which is lesser known. Fine needle aspiration cytology is a simple, cost effective and outdoor patient procedure for diagnosis as well as management of this entity. Here, we present a case of four months old infant who presented with left axillary suppurative lymphadenopathy.

**Keywords:** Bacilli Calmette-Guerin, infant, lymph node.

### INTRODUCTION

Bacilli Calmette-Guerin (BCG) is a live attenuated vaccine included in the expanded immunization program by World Health Organisation (WHO) from 1974. [1] In India it is included in National immunization scheme and is administered intradermally at birth in left deltoid muscle to decrease the serious consequences of tuberculosis in our country. Although, it has a low efficacy but is helpful in prevention of disseminated disease and tubercular meningitis in children. [2] There are low incidence of post vaccination complications

with ipsilateral lymphadenopathy being most common.

### CASE REPORT

A four months old male child presented with left axillary lymph node enlargement to the department of pediatric surgery. The swelling was present from last 20 days, measuring 2x2 cm in size and the overlying skin was inflamed. The swelling was firm, mobile, tender and fluctuant. The BCG vaccine scar was present on the left arm and she had history of BCG vaccine on day one after birth. There was no history of fever, loss of weight/appetite or failure to thrive. Also, there no history of tubercular contact. The patient was referred to the department of cytopathology for fine needle aspiration cytology.

On aspiration pus was yielded. Smears prepared showed necrosis only. Ziel Nelson stain for acid fast bacilli was positive. On the basis of clinical and cytopathological findings a diagnosis of BCG vaccine associated suppurative lymphadenitis was given.(Figure 1)

After FNAC the swelling decreased in size and subsided in another 1.5 months. No further treatment was required. On follow up for three months the patient is free of any swelling or any other symptoms and is doing well. This further supported the final diagnosis.

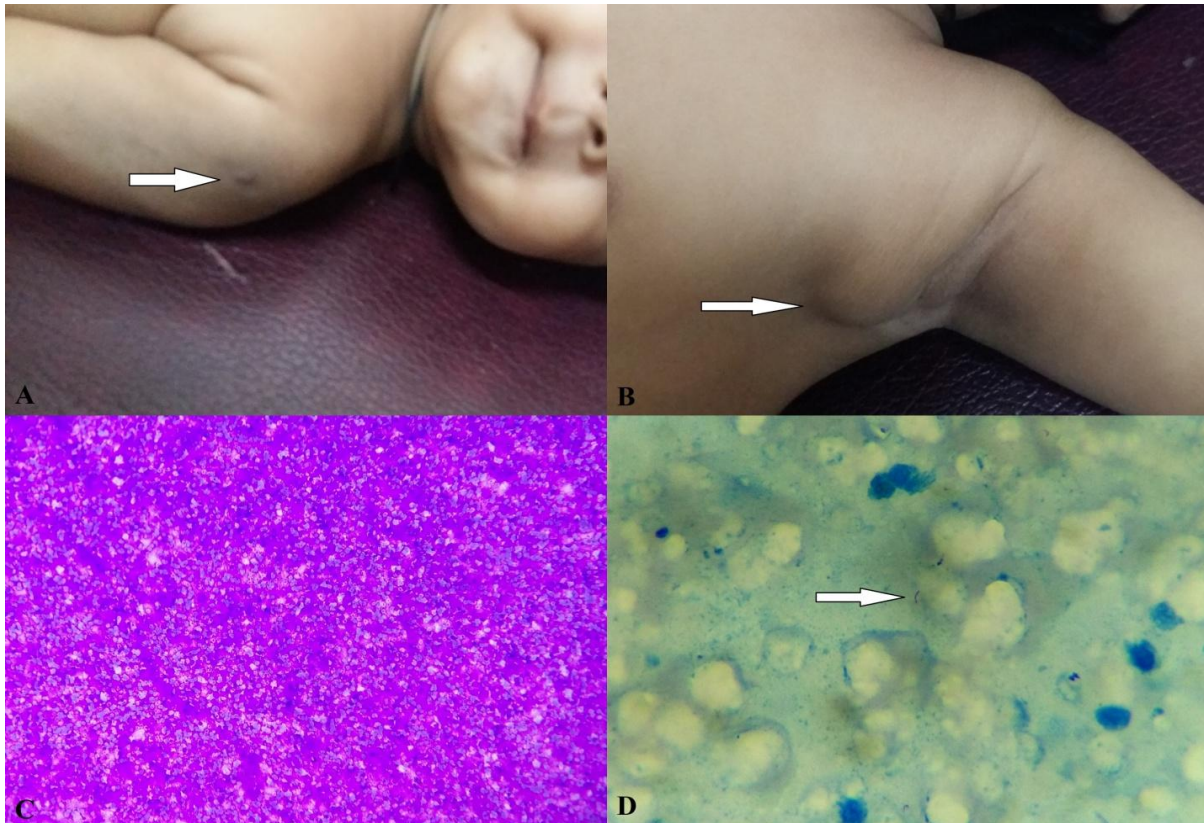


Fig 1.(a) Clinical Photograph showing left axillary swelling. (b). Scar mark noted over left deltoid. (c) FNAC smear showing necrosis (Giemsa, 200X). (d). Ziel Nelson stain showing acid fast bacilli. (oil immersion ).

## DISCUSSION

The BCG vaccine strains most commonly used are Mycobacterium bovis-Pasteur 1173 P2, Danish 1331, Glaxo 1077 and Tokyo 172. Every year approximately 120 million doses of BCG vaccine are used worldwide. [3,4]

On administration of injection in left deltoid the BCG strains start dividing at the local site forming an indurated nodule followed by ulceration and healing over next 10 to 12 weeks. This along with the lymph node reaction forms a primary complex simulating the tubercular infection. The incidence of complications varies from 0.1% to 17% with lymphadenitis being the most common with male predominance. [3]

The causative factors are early age of infant, immunodeficiency, subcutaneous injection instead of intradermal, higher dose or strain related factors. [3,5] The lymphadenitis can be suppurative or nonsuppurative. The commonly involved lymph nodes are ipsilateral axillary, cervical or supraclavicular.

The definitive diagnosis can be made by culture or Gene XPERT. [6] Also, absence of systemic features, isolated lymph node enlargement, absence of failure to thrive and family history also supports BCG adenitis. There is no need of treatment in nonsuppurative lymphadenitis.

The management of suppurative lymphadenitis includes aspiration by needle rather than incision and drainage which prevent persistent draining wound and an ugly scar. This also avoids the use of local anaesthetics in the infant. [1] Surgical repair is required in nonhealing wounds as concluded by S. Abbas Banani and Alborzi. [3,7] Antitubercular drugs do not shorten duration or prevent the occurrence of suppurative lymphadenitis, thus are not recommended.

## CONCLUSION

BCG lymphadenitis needs a high index of suspicion to be diagnosed clinically in infants. FNAC along with clinical presentation and history is all that is needed

for correct and early diagnosis as well as management of these cases to prevent unnecessary administration of antitubercular drugs in infants. Awareness of this entity, compilation of incidence of various complications should be done at all peripheral as well as higher centers.

#### REFERENCES

1. Nagi E, Dayel A, Alshehri M, Alzahrani M, Sami A, Suliman A, *et al.* Bacillus Calmette Guerin vaccine related lymphadenitis in children: Management guidelines endorsed by the Saudi Pediatric Infectious Diseases Society (SPIDS). *Int J Pediatr Adolesc Med* 2015;2:89-95.
2. Bannon MJ. BCG and tuberculosis. *Arch Dis Child* 1999;80:80-3.
3. Pal S, Chakarabarti S, Phukan JP, Biswas S, Sinha A, Sinha R, *et al.* Role of needle aspiration in diagnosis and management of suppurative Bacille Calmette-Guerin adenitis: An institutional study of 30 cases. *J Lab Physicians* 2015;7:21-5.
4. Luca S, Mihaescu T. History of BCG vaccine. *Maedica (Buchar)* 2013;8:53-8.
5. Behjati B, Ayatoallahi J. Post BCG lymphadenitis in vaccinated infants in Yazd, Iran. *Iran J Pediatr* 2008;18:351-6.
6. Goraya JS, Viridi VS. Bacille Calmette-Guérin lymphadenitis. *Postgrad Med J* 2002;78:327-9.
7. Banani SA, Alborzi A. Needle aspiration for suppurative post-BCG adenitis. *Arch Dis Child* 1994;71:446-7

How to cite this article: Kumari M, Singh M, Punhani P. Suppurative Bacille Calmette-Guerin (BCG) lymphadenitis in an infant- an unexplored entity. *International Journal of Science & Healthcare Research*. 2019; 4(4): 67-69.

\*\*\*\*\*