

An Unusual Presentation of Basal Cell Adenoma of Ectopic Salivary Gland Tissue: A Case Report

Dr. Sanchita Kalita¹, Dr. Smrity Rupa Borah Dutta²

¹Senior Resident, Gauhati Medical College and Hospital, Assam, India

²Associate Professor (ENT), Silchar Medical College and Hospital, Assam, India

Corresponding Author: Dr. Sanchita Kalita

ABSTRACT

Salivary gland tumors constitute about 2% to 6.5% of all head and neck region tumors. Basal cell adenoma (BCA) of the salivary glands is an uncommon benign epithelial tumour.

It is considered as a low-grade malignant tumour with a high recurrence rate and, in general, good prognosis. BCA represents 54% of monomorphous adenomas and 1-3% of major salivary glands tumours. Most of these tumors are located on the parotid region (80%). In this case report, we are highlighting an unusual location of this not so commonly encountered tumour and its related diagnostic confusion.

Key words: Salivary gland, Basal Cell Adenoma, uncommon

INTRODUCTION

Salivary gland tumors constitute about 2% to 6.5% of all head and neck region tumors. Because of its varied types, it is hard to diagnose the tumor definitely. Basal cell adenoma (BCA) of the salivary glands is an uncommon benign epithelial tumour, being recognised as an independent entity in the Second Edition of the Salivary Gland Tumours Classification of the World Health Organization (WHO).^[1,12] It is considered as a low-grade malignant tumour with a high recurrence rate and, in general, good prognosis. BCA represents 54% of monomorphous adenomas and 1-3% of major salivary glands tumours.^[4] Most of these tumors are located on the parotid region (80%). Also most of the parotid benign tumors are located on the superficial lobe. More than 80% of basal cell adenomas arise in the major salivary gland, mostly the

parotid gland. Other rare sites include upper lip, buccal mucosa, lower lip, palate and nasal septum.^[2,3,10]

Basal cell adenoma (BCA) is a rare neoplasm consisting of a monomorphic population of basaloid epithelial cells and accounts for 1-3% of all salivary gland tumors.^[1] Epidemiologically, these tumours frequently affect patients between their fifth and seventh decades, in contrast to observations in benign mixed tumours. In the opinion of most authors, there is a female preponderance, but other authors report a similar frequency for both genders.^[5,6]

Histologically, four characteristic patterns have been described: solid, trabecular, tubular and membranous. Basically, BCA consists of a monomorphic population of basaloid epithelial cells, organized with a prominent basal cell layer and distinct basement membrane-like material; however, it lacks the myxochondroid stromal component, which distinguishes it from the pleomorphic adenoma.

CASE REPORT

The patient, a 60 yrs old female patient, presented with a painless globular swelling below and behind the left ear lobule. (Figure 1) The patient had 1st noticed the swelling, about pea-size, below her left ear lobule about 10 yrs back. The swelling had gradually increased in size, and during the time of presentation was about 3.5 x 4 sq cm in dimension.

On examination, the swelling was well circumscribed, firm in consistency, globular in shape, non-tender, non-fluctuant, non transilluminant, non pulsatile, free from the overlying skin, freely movable, with prominence of vessels on the overlying skin, with no bruit on auscultation. There was a suspicion of a vascular lesion/neoplasm; because of which MRI was done.

MRI of the swelling revealed a circumscribed, well defined T1 hypointense and T2 iso to hyperintense lesion measuring approximately 3.3 x 3.4 x 3.8 cu cm in the subcutaneous plane just behind the left ear lobule. The lesion shows few internal flow voids. A small T1 hyperintense focus showing blooming on GRE sequence suggestive of hemorrhage was noted in the lesion. On post contrast study, the lesion showed significant heterogenous enhancement. There was evidence of a small arterial feeder entering the lesion, arising from a branch of posterior auricular artery. However no definitive draining vein was visualized. The parotid could be separately delineated. (Figure 2)

An Ultrasound guided FNAC from the swelling revealed blood mixed material from the aspirate, which showed mostly RBC in pinkish background, scattered chronic inflammatory cells, small clusters of epithelial cells with round bland nuclei, and abundant cytoplasm and pinkish material. The features were suggestive of salivary gland neoplasm (? Pleomorphic Adenoma).

As the parotid was separately identified from the swelling, and was normal, the swelling was planned to be excised with preservation of the parotid. Excision biopsy of the under Local Anesthesia was carried out as the swelling was well localized. Following skin incision, the capsule of the swelling could be identified and the dissection was carried out along the plane of the capsule. (Figure 3) The whole mass with the intact capsule was carefully dissected; no fascial or septal continuity to the parotid gland was noted. The feeder artery was ligated and the

resected specimen was sent for Histopathological examination.

HPE report revealed isomorphic basaloid cells with prominent basal cell layer, distinct basement membrane-like structure and no mucoid stromal component, features suggestive of Basal Cell Adenoma. (Figure 4) [7,11]

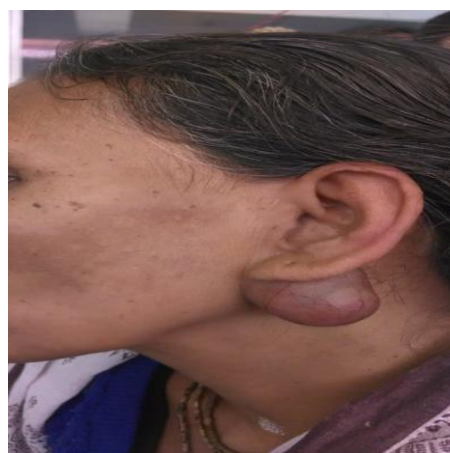

Figure 1: Showing the left juxta-auricular lesion as described above

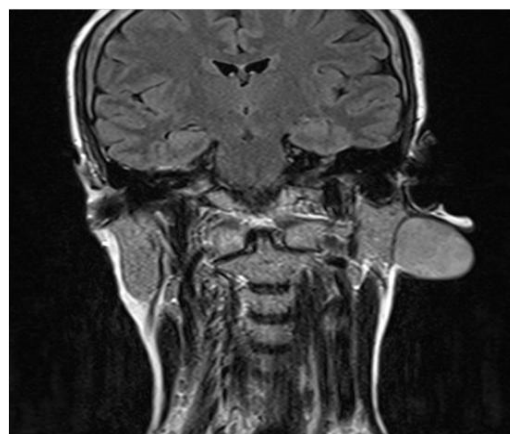


Figure 2: Showing a coronal slice of the MRI (details described above)

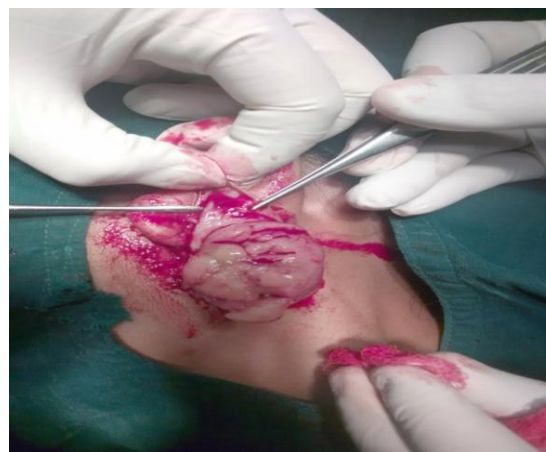

Figure 3: Showing intraoperative picture of the well encapsulated lesion

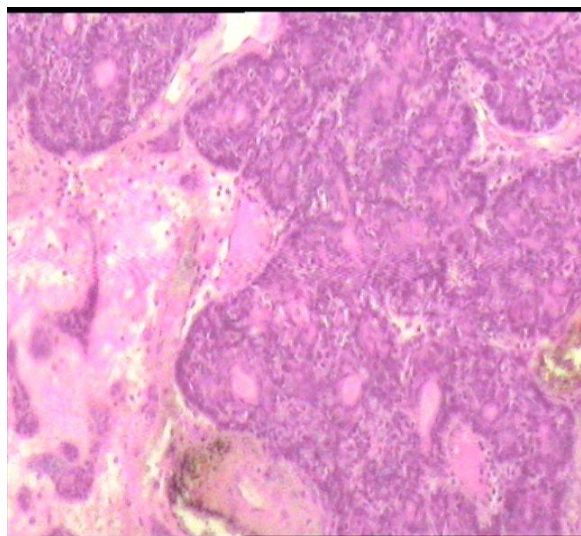


Figure 4: HPE report revealed isomorphic basaloid cells with prominent basal cell layer, distinct basement membrane-like structure and no mucoid stromal component, features suggestive of Basal Cell Adenoma [7]

DISCUSSION

The most common tumor of parotid is pleomorphic adenoma (65%). BCA constitutes only 1-3% of all salivary gland tumors. Monomorphic adenoma differs from pleomorphic adenoma histologically. [2] Monomorphic adenoma can be basaloid and non basaloid type. BCA, a rare benign epithelial tumor with monomorphous and uniform basaloid cells is a subtype of monomorphic adenoma. It is commonly seen on the parotid gland; can also be detected on upper lip and minor salivary gland. [3-5] It affects mostly adults and females, [6,8,9] in 5th and 6th decades of life. Clinically it has an indolent course, and is usually asymptomatic, painless, well demarcated and freely mobile.

In our case, the lesion was seen to be just adjacent to the left parotid region, posterior and inferior to the ear lobule, slow growing but otherwise asymptomatic and was well demarcated. Initial confusion, regarding a vascular lesion because of prominent vessels over the swelling, was however ruled out by MRI. FNAC was suggestive of pleomorphic adenoma of salivary gland; though MRI showed that the lesion was adjacent to but separate from the parotid plane. Following excision biopsy, the histopathological examination revealed Basal Cell Adenoma. The standard

treatment plan of BCA has been mentioned to be Superficial/ Total Parotidectomy in literature; to avoid the high rate of recurrence following enucleation. But enucleation has been reserved for unusual presentation of BCA, for example in deep lobe of parotid; to avoid the morbidity related to Total Parotidectomy. The unusual site of BCA in our study, adjacent to but separate from the parotid, has lead to the decision of local excision without superficial parotidectomy. The tissue of origin of BCA is most likely to be accessory or ectopic parotid tissue. The patient was being followed till two years; no recurrence was reported.

Thus, though rare, BCA can very easily be missed because of the dilemma of misdiagnosis as Pleomorphic adenoma by FNAC. Also, deep lobe BCA could be confused with malignancy. Moreover, attention should also be paid to the unusual location of the swelling, as in our case. Hence a complete investigative workup is mandatory to decide on the best surgical option.

Abbreviations:

BCA=Basal Cell Adenoma, FNAC=Fine Needle Aspiration Cytology, MRI=Magnetic Resonance Imaging, GRE=Gradient echo, HPE=Histopathological Examination

REFERENCES

1. Seifert G, Sobin LH. The World Health Organization's Histological Classification of Salivary Gland Tumors. *Cancer* 1992;70: 379-85.
2. Mintz GA, Abrams AM, Melrose RJ. Monomorphic adenomas of the major and minor salivary glands. Report of twenty-one cases and review of the literature. *Oral Surg* 1982;53:375-86.
3. Bernacki EG, Batsakis JG, Johns ME. Basal cell adenoma. Distinctive tumor of salivary glands. *Arch Otolaryngol* 1974;99:84-8.
4. Luna MA, Tortoledo ME, Allen M. Salivary terminal analogue tumors arising in lymph nodes. *Cancer* 1987;59:212-24.
5. Chaudhry AP, Cutler LS, Satchidanand S, labay G, Sunderraj M. Ultrastructure of monomorphic adenoma (ductal type) of the

- minor salivary glands. Arch Otolaryngol 1983;109:118-22.
6. Fantasia JE, Neville BW. Basal cell adenomas of the minor salivary glands. A clinicopathologic study of seventeen new cases and review of the literature. Oral Surg 1980;50:433-40.
 7. Nagao K, Matsuzaki O, Saiga H, Sugano I, Shigematsu H, Kaneko T, et al. Histopathologic studies of basal cell adenoma of the parotid gland. Cancer 1982;50:736-45.
 8. Dardick I, Daley TD, Van Nostrand AWP. Basal cell adenoma with myoepithelial cell-derived stroma: a new major salivary gland tumor entity. Head Neck Surg 1986;8:256-67.
 9. Min BH, Miller AS, Leifer C, Putong PB. Basal cell adenoma of the parotid gland. Arch Otolaryngol 1974;99:88-93.
 10. Zabaleta M, Mollá FJ, Salazar F, Erdozain E, Sánchez L. Monomorphic adenoma of basal cells in a minor salivary gland. Acta OtorrinolaringolEsp 1997;48:169-72.
 11. Ogawa I, Nijai H, Takata T, Miyauchi M, Ito H, Ijuhin N. The cellular composition of basal cell adenoma of the parotid gland: an immunohistochemical análisis. Oral Surg Oral Med Oral Pathol 1990;70:619-26.
 12. Evans RW, Cruickshank AH. Epithelial tumors of the salivary glands. Major Probl Pathol 1970;1:1-299.

How to cite this article: Kalita S, Dutta SRB. An unusual presentation of basal cell adenoma of ectopic salivary gland tissue: a case report. International Journal of Science & Healthcare Research. 2018; 3(2): 122-125.
